

## **Chapter 94: Anatomy**

**Daniel O. Graney, Paul W. Flint**

Although the colloquial term for the larynx is the *voice box*, one should remember that its function in the earliest animal forms was quite different. The beginnings of a larynx appeared first in primitive lungfish as a few sphincter muscle fibers to protect the air sac from water. Only later in the evolutionary scheme did the larynx begin to function for the purpose of phonation (Negus, 1949).

Although the larynx appears to be a complicated structure when first studied, it is in fact rather simple in its basic anatomic form. Conceptually, this form can be described as a skeletomembranous framework on which a series of muscles are superimposed for the purpose of altering the membrane position during varying laryngeal functions (that is, respiration, phonation, and deglutition). An understanding of this basic framework is paramount to visualizing the function of the various muscles as they affect the actions of the true and false vocal cords (also referred to as *folds*).

## **Skeletomembranous Framework of the Larynx**

### **Hyoid bone**

The hyoid bone is considered a lingual bone because of the tongue musculature attached to it. It also serves, however, as an attachment for the larynx, specifically the thyroid cartilage via the thyrohyoid membrane and the extrinsic muscles of the larynx. For these reasons the hyoid bone should be included as part of the laryngeal apparatus (Figs. 94-1 to 94-3). The hyoid bone is a U-shaped bone consisting of three named parts: the body and paired great and lesser horns. Embryologically, the hyoid bone is derived from mesodermal cells that form cartilaginous masses in the second and third branchial arches. Remodeling and fusion of these cartilages form the lesser horn, derived from the second branchial arch; the body and greater horn are derived from the third branchial arch. In addition, the proximal portion of the second branchial arch forms the stapes of the middle ear, styloid process, and stylohyoid ligament. In adults the styloid process, stylohyoid ligament, and lesser horn of the hyoid bone symbolize the line of the second branchial arch cartilage.

**Fig. 94-1.** Lateral view of laryngeal bones and cartilages.

### **Laryngeal cartilages**

The major cartilages of the larynx are the thyroid, cricoid, epiglottic, and paired arytenoids. These develop from the cartilage elements of the fourth, fifth, and sixth branchial arches.

### *Thyroid cartilage*

The thyroid cartilage resembles a sharply flexed, shield-like structure and has several important landmarks, namely, the paired superior and inferior horns, the lateral plates or laminae, and the thyroid notch. In lateral profile the notch and midline of the thyroid cartilage form an angle projecting anteriorly - the laryngeal prominence (see Figs. 94-1 and 94-2). Articulations of the inferior horn with facets on the posterior arch of the cricoid form important synovial joints (the cricothyroid joints) that facilitate a hinge motion between the two cartilages. In addition to their functional significance, these joints, like other synovial joints of the body, are subject to arthritis. This fact is of particular interest to the otolaryngologist - head and neck surgeon, since patients with cricothyroid arthritis frequently complain of odynophonia. Impaired mobility of the cricothyroid joint may follow, resulting in loss of pitch range and vocal fatigue. Physical findings suggestive cricothyroid joint involvement include bilateral vocal fold bowing, inability to lengthen the vocal folds with attempts to elevate pitch, and loss of normal laryngeal crepitation during manual manipulation of the cricoid and thyroid cartilages.

**Fig. 94-2.** Posterior view of laryngeal bones and cartilages.

### *Cricoid cartilage*

The cricoid cartilage is the only complete skeletal ring for the airway. Classical descriptions compare it to a signet ring with a broad arch located posteriorly, tapering anteriorly to form a narrower arch. The thyroid and cricoid cartilages are attached anteriorly in the midline by a median cricothyroid ligament (see Figs. 94-1 and 94-3). Although these cartilages are composed of hyaline cartilage, it is not uncommon for them to become calcified later in life. Ossification may also occur, even to the stage at which a narrow cavity is

formed. For these reasons it is not uncommon to encounter fractures of these cartilages after blunt trauma.

**Fig. 94-3.** Sagittal section of laryngeal bones and cartilages.

### *Epiglottic cartilage*

The cartilage of the epiglottis is a leaflike structure composed primarily of elastic cartilage. The mucosa covering its anterior surface is composed of stratified squamous epithelium. Posteriorly, near the inlet of the larynx, the epithelium is pseudostratified, ciliated, and columnar. The inferior part, or stem, of the cartilage is attached to the posterior aspect of the angle of the thyroid cartilage (Fig. 94-3). The anterior midportion of the epiglottic cartilage attaches to the tongue by three mucosal folds: the median glossoepiglottic fold and the paired lateral glossoepiglottic folds. The spatial arrangement of these folds forms paired fossae, the lingual valleculae, which are situated between the base of the tongue and the anterior aspect of the epiglottis. Another feature of the epiglottic cartilage relates to the attachment of the quadrangular membrane. The details of this membrane and its attachment are discussed later in the chapter.

### *Arytenoid cartilages*

The arytenoid cartilages are a pair of pyramid-shaped structures that articulate with facets on the superior surface of the posterior arch of the cricoid cartilage. There are four major landmarks on the arytenoid cartilage: the concave articular base, the apex, a muscular process projecting laterally, and a vocal process projecting anteriorly (Figs. 94-2 to 94-5). A small mass of cartilage, the corniculate cartilage, usually articulates with the apex of the arytenoid and is located within the inferomedial part of the aryepiglottic fold. In the midline the mucosa forms a shallow notch between the two corniculate cartilages, known as the

posterior commissure, a reference landmark during laryngoscopy. On the lateral aspect of the corniculate cartilages, within the aryepiglottic folds, are the cuneiform cartilages. During laryngoscopy the corniculate and cuneiform cartilages appear as small, paired swellings in the aryepiglottic folds lying on either side of the posterior commissure.

**Fig. 94-4.** Sagittal section of laryngeal membranes.

The cricoarytenoid joint (a synovial joint) may also be involved with arthritis. This process should be considered in all adult patients with idiopathic vocal fold motion impairment, as well as in patients with impaired motion after prolonged endotracheal intubation.

### **Laryngeal Membranes**

The important functional framework of the larynx consists not only of its cartilages, but also of two membranes: the quadrangular membrane and the triangular membrane. These are paired membranes that, in part, form the structural base for the vocal folds.

#### **Quadrangular membrane**

The quadrangular membrane begins at the lateral border of the epiglottic cartilage and spans the space between the epiglottic and the arytenoid cartilages (see Figs. 94-4 and 94-5). The posterior border of the membrane is shorter than the anterior border. Posteriorly, it is only as tall as the arytenoid to which it attaches, following a line from the apex of the arytenoid to its vocal process. Anteriorly, the height of the quadrangular membrane is the same as that of the epiglottic cartilage. The superior border of the membrane is free and has an oblique course from the upper part of the epiglottis to the corniculate cartilage. The inferior border of the quadrangular membrane extends from the inferior point of attachment of the epiglottic cartilage on the thyroid cartilage to the vocal process of the arytenoid cartilage. Thus the membrane has four borders: anterior and posterior borders, which are fixed, and superior and inferior borders, which are free (Figs. 94-4 to 94-6). Both the upper

and lower free borders of the membrane are thickened to form ligaments: the aryepiglottic and the vestibular folds, respectively. In lateral profile the aryepiglottic ligament is concave, whereas the vestibular ligament is convex (see Fig. 94-4).

### **Triangular membrane**

In lateral profile the triangular membrane has a narrow base, the midline, where it is attached to the thyroid and cricoid cartilages, projecting to an apex, which is the vocal process of the arytenoid cartilage (Fig. 94-4). The superior border of the triangular membrane begins at the thyroid cartilage, extending posteriorly as a concave line to the vocal process. This edge of the membrane is free on its medial and lateral surfaces and is thickened, forming the vocal ligament. The inferior border of the triangular membrane, however, is attached to the cricoid cartilage (Figs. 94-4 to 94-7).

**Fig. 94-5.** Posterior laryngeal membranes  
(right arytenoid cartilage moved laterally).

From the beginning, one can see that the quadrangular and triangular membranes and, in particular, the vestibular and vocal ligaments form the structural base for the formation of the vocal folds.

### **Laryngeal mucosa**

The next step in the construction, so to speak, of the larynx is to cover the membranes with muscle and mucosa. This covering is best viewed in a coronal section of the larynx (see Fig. 94-6). Tracing the mucosal lining of the trachea upward from the first tracheal ring, one can see it move medially, following the contour of the triangular membrane (cricothyroid membrane). At the point of the vocal ligament, the mucosa is reflected laterally to form a cul-de-sac, namely, the laryngeal ventricle or sinus. The mucosa continues medially, covering the inferior aspect of the vestibular ligament, where it forms the false vocal fold. From this point the mucosa extends superiorly on the medial surface of the quadrangular membrane until it reflects laterally over the aryepiglottic ligament, thus establishing the aryepiglottic fold.

**Fig. 94-6.** Coronal section of larynx.

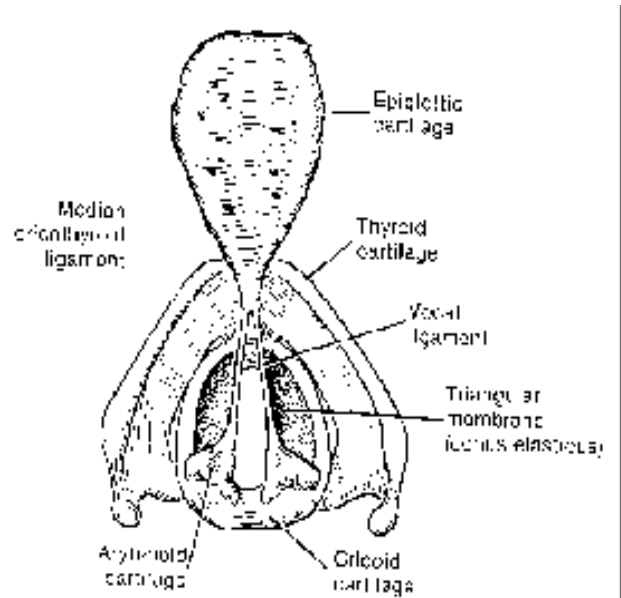
Essentially all of the mucosa from the trachea to the aryepiglottic fold is composed of a pseudostratified, ciliated, columnar epithelium, except for the covering of the true vocal folds, which is stratified squamous epithelium. Tubuloalveolar glands are abundant, particularly in the region of the ventricle, and provide lubrication for the vocal folds. At the point of the aryepiglottic fold, the mucosa becomes stratified squamous epithelium and covers the lateral surface of the quadrangular membrane, dipping down into the space between the quadrangular membrane and the thyroid cartilage before turning superiorly on the medial surface of the thyroid cartilage. This forms a pear-shaped mucosal recess, the piriform recess, which is closed anteriorly but open into the pharynx posteriorly. From the lateral wall of the piriform recess, the mucosa ascends on the thyrohyoid membrane, on the hyoid bone, and onto the surface of the tongue and floor of the mouth.

In review, three important folds are established: the aryepiglottic fold (superior border of the quadrangular membrane), the false vocal fold (inferior border of the quadrangular membrane), and, finally, the true vocal fold, which is formed by the mucosal covering of the upper surface of the triangular membrane. These three folds, in association with their muscles, form what has been described as a tri-level sphincter mechanism (aryepiglottic fold, vestibular fold, and vocal fold) that regulates the airway (Pressman and Kelemen, 1955). Although the accuracy of this mechanism is open to question, it is easy to visualize conceptually and can serve as a point of discussion. The mechanism of these sphincters is discussed following the description of the laryngeal muscles.

### **Laryngocele**

After becoming familiar with the topography of the mucosal lining in a coronal section (see Fig. 94-6), one can easily follow the formation of a laryngocele. A laryngocele is a herniation of the ventricular mucosa. Some authors use the term *saccule* for this mucosal configuration, reserving the term *ventricle* for the space. Increased intraluminal pressure is believed to cause enlargement of the ventricular mucosa, which, because of its anatomic relationships, expands upward in the pathway of least resistance. Inferiorly, the triangular membrane (conus elasticus) blocks the way. Laterally the thyroid cartilage directs the

enlarging sac upward. At this stage of development the herniation is classified as an internal laryngocele. Note that as the saccule enlarges upward, it occupies the piriform fossa. If herniation continues, the sac pierces the thyrohyoid membrane and the herniation is now classified as an external laryngocele. When distended by the Valsalva maneuver, the saccule becomes a tympanic mass, ballotable in the carotid triangle of the neck.



**Fig. 94-7.** Larynx viewed from above (quadrangular membrane removed).

## Laryngeal Musculature

### Extrinsic and accessory musculature

Classification of the laryngeal musculature varies with different authors. Most authors agree that there is an intrinsic group of muscles that act directly on the quadrangular membrane and indirectly on the triangular membrane by movement of the arytenoid cartilages. Classification of the extrinsic group of muscles varies, however. Some authors report only a single extrinsic muscle, the cricothyroid, whereas others group the cricothyroid muscle with the intrinsic group and classify some of the suprahyoid and infrahyoid muscles as extrinsic laryngeal muscles because they can elevate or depress the larynx. For instance, the digastric, geniohyoid, stylohyoid, stylopharyngeal, and thyrohyoid muscles can elevate the larynx and therefore may be classified as extrinsic muscles. Similarly, the sternothyroid, sternohyoid, and omohyoid muscles may be included as extrinsic muscles because of their action as depressors of the larynx. This chapter defines the cricothyroid as an extrinsic muscle of the larynx and classifies those muscles that elevate or depress the larynx as accessory laryngeal muscles.

### Intrinsic musculature

Although doing so may be somewhat contrived, it may be helpful (from a functional point of view) to think of two sets of three muscles. One set is associated with the



quadrangular membrane and includes the thyroarytenoid, thyroepiglottic, and aryepiglottic muscles. The other set acts on the arytenoid cartilage and consists of the posterior cricoarytenoid, lateral cricoarytenoid, and arytenoid muscles (Figs. 94-8 and 94-9). A sixth muscle, the vocalis muscle, is a longitudinally arranged group of muscle fibers paralleling the vocal fold, although in reality these fibers are probably part of the thyroarytenoid muscle.

**Fig. 94-8.** Lateral view of laryngeal muscles and nerves (one half of thyroid cartilage and hyoid bone removed).

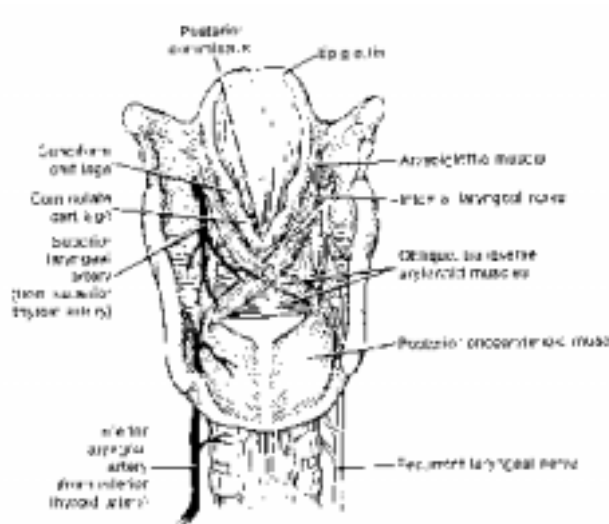
#### *Muscles of quadrangular membrane*

The muscles associated with the quadrangular membrane are quite easily visualized from a lateral view of the quadrangular membrane surface (see Fig. 94-8). A single sheet of muscle arises from the posterior midline of the thyroid cartilage and sends fibers either superiorly, toward the epiglottis, or more horizontally, toward the arytenoid muscle. Division of these fibers is somewhat arbitrary in the sense that those coursing upward toward the epiglottis are designated as the thyroepiglottic muscle, whereas those directed toward the arytenoid are designated as the thyroarytenoid muscle, which makes up the bulk of the muscle group. As described above, the deep part of this muscle forms the vocal muscle. A third set of fibers paralleling the border of the aryepiglottic fold and underlying the mucosa is designated as the aryepiglottic muscle. The latter muscle aids in closing the aditus, or inlet, of the larynx, whereas the thyroarytenoid muscle acts in approximating the false vocal cords.

#### **Muscles of triangular membrane and arytenoid cartilage**

The cricoarytenoid muscles arise, as their name implies from either the posterior or the lateral surface of the cricoid cartilage and insert on the arytenoid cartilage (see Figs. 94-8 and 94-9). The muscles are somewhat fan shaped, with the apex of their fibers inserting on the muscular process of the arytenoid cartilage. The origin of the posterior cricoarytenoid muscle is quite expansive, essentially covering the entire posterior aspect of the cricoid

lamina. The fibers arising from the more superior aspect tend to be horizontal, whereas those arising from the inferior aspect of the lamina have a more oblique course. The lateral cricoarytenoid muscle is a smaller, more bandlike muscle that arises from the anterior aspect of the cricoid arch and sends its fibers in a posterosuperior direction to insert on the muscular process.



**Fig. 94-9.** Posterior view of laryngeal muscles, nerves, and arteries.

The third muscle associated with the arytenoid cartilages is the arytenoid muscle. These fibers arise from the posterior and lateral aspect of the arytenoid, crossing in a horizontal manner to the opposite arytenoid cartilage. Some authors describe an oblique arytenoid muscle extending from the muscular process toward the aryepiglottic fold of the opposite side. These fibers are nothing more than the inferior aspect of the aryepiglottic muscle. Beginning superiorly, the normal course of the aryepiglottic muscle from the epiglottic cartilage is downward along the aryepiglottic fold to the point of the arytenoid muscle, where its fibers continue across the midline to the muscular process of the arytenoid cartilage. As the two aryepiglottic muscles sweep inferiorly, they cross over the arytenoid muscle, forming an X-shaped figure.

### Vocal Fold Function

In recent years several studies have reinvestigated the anatomy of the cricoarytenoid joints and their musculature. The interpretations of these studies challenge some of the traditional concepts of laryngeal muscle function that were held for the first part of this century (Fink, 1975; Sellars and Sellars, 1983). Fink emphasized analyzing laryngeal musculature during various functional states of the larynx: respiratory (expiratory and inspiratory), phonatory, stress closure, and swallowing. Most statements of muscle actions are simplistic and imply an all-or-none isometric contraction. For example, the most elementary student of anatomy knows the triceps muscle extends the elbow and the biceps flexes it. Is this statement true, however, if the elbow is extended while the hand holds a 5-pound weight? Of course not. Under these conditions the biceps releases tension slowly while the force of

gravity extends the elbow. If the biceps simply turned off and the triceps contracted, about 10 foot-pounds of energy would be dissipated on the anterior thigh. In the case of the larynx, tensile forces on the laryngeal membranes during inspiration or phonation may alter the contractile state of the intrinsic muscles; thus the specific action of a muscle may not always be obvious.

Each functional state requires certain positions for the vocal folds: they may either be flattened, as in maximal inspiration, or in tight approximation, as in effort closure. In phonation only the true vocal folds are opposed, whereas in effort closure both true and false folds are approximated, in addition to closure of the laryngeal ventricle. Finally, during swallowing, maximal sealing of the airway is accomplished, not only by sphincteric action of the aryepiglottic muscles closing the aditus, but also by elevation of the larynx and apposition of the tongue base to the epiglottis.

### **Respiration**

During quiet respiration, movement of the vocal cords is relatively minor. The glottis is in a rest position and only opens slightly with inspiration. During maximal inspiration, however, the larynx is drawn downward by the effect of the sternothyroid and sternohyoid muscles, as well as by traction on the trachea. Both true and false vocal folds flatten (unfold) against the lateral wall of the larynx to maximally open the airway. For the vestibular and vocal folds to flatten and open the glottis, the arytenoid cartilages (the posterior attachment of both the vestibular and vocal folds) must be abducted and rotated outward. Previous concepts of this action described the arytenoids rotating about a vertical axis and sliding laterally because of the action of the posterior cricoarytenoid muscle, the result being a pentagonal glottic opening formed by the paired vocal folds, vocal processes of the arytenoids, and an interarytenoid mucosal fold. The current interpretation of this action disputes the original concept on at least three points. First, the saddlelike architecture of the cricoarytenoid joints prevents rotation until the arytenoids are abducted on the slope of the cricoid. Second, the apparent rotation is in reality a backward rocking of the arytenoid, which points the vocal process laterally. Third, the lateral cricoarytenoid and cricothyroid muscles in maximal inspiration probably abduct the arytenoids, and the posterior cricoarytenoid assists only in the rocking of the arytenoid to point the vocal process laterally (Fink, 1975; Sellars and Sellars, 1983; Suzuki et al, 1970). In addition, Fink and Demarest (1978) have suggested that tension on the quadrangular membrane (a spring tension caused by the superior attachment of the membrane to the epiglottis and the consequent pull on the epiglottis by its attachment to the stabilized hyoid bone) assists in abduction because it provides a lateral force vector on the arytenoid cartilage. One should note that during maximal inspiration the larynx is under tension by opposing forces: a downward force exerted by the trachea and an upward force exerted by the suprahyoid muscles, which act to stabilize the hyoid bone. Cessation of inspiration releases these forces, allowing the recoil energy that has been developed in the elastic tissue to return the folds to the respiratory rest position.

Physiologic studies have further delineated laryngeal muscle function during respiration. Electromyography (EMG) of the cricothyroid muscle has demonstrated evidence of respiratory function during both deep inspiration and expiration (Woodson, 1990). Cricothyroid contraction, by itself, results in elongation of the vocal fold and slight adduction. With simultaneous contraction of the cricothyroid and the posterior cricoarytenoid muscle, the

glottis is both lengthened and widened, thus reducing airway resistance. Further, both cricothyroid EMG activity and posterior cricoarytenoid EMG activity have been shown to increase in response to a rising arterial CO<sub>2</sub>, decrease in arterial O<sub>2</sub>, and upper airway obstruction or negative upper airway pressure (Mathew et al, 1988; Sant'Ambrogio et al, 1985; Woodall and Mathew, 1988; Woodson, 1990). Conversely, a decrease in arterial CO<sub>2</sub>, an increase in arterial O<sub>2</sub>, and tracheotomy result in decreased cricothyroid and posterior cricothyroid muscle EMG activity.

## **Phonation**

Movement of the vocal folds has fascinated students of phonation since Manuel Garcia first observed the phenomenon with a dental mirror in 1845. Approximately 100 years later, Farnsworth (1940) was able to study the dynamics of vocal fold movement in slow motion by analyzing high-speed (4000 frames/sec) cinematographic films produced in the Bell Telephone Laboratories. These films clearly illustrated a horizontal (side-to-side) vibratory motion of the vocal folds, as well as a slight vertical motion of the vocal folds, as the folds opened. The mechanism by which the folds oscillate or vibrate was debated for several years, but since 1960 the myoelastic-aerodynamic theory (van den Berg, 1958), rather than the neuromuscular (neurochronaxic) theory (Husson, 1950), has been accepted in principle as an explanation of the biomechanical events of phonation. For a review of these arguments the reader should consult the works by van den Berg (1958), Fink (1975), Kirchner (1980), and Stell and Evans (1979).

The myoelastic-aerodynamic theory requires that a mass of subglottic air be compressed by thoracic respiratory muscles while the vocal folds are adducted and tensed. At the moment glottic resistance is overcome by the pressure of the compressed air column, the folds open, allowing air to flow through the glottis and reduce subglottic pressure. Elastic recoil of the vocal folds reestablishes glottic resistance, and, as long as subglottic pressure is maintained, a cyclic movement or horizontal oscillation of the vocal folds will continue. The larynx thus serves as an acoustic wave generator, producing a tone that can be modulated by the supraglottic anatomy. The frequency of vocal cord vibration and hence the frequency of the phonated tone are related mathematically to subglottic air pressure, airflow, and glottic resistance. In contrast to the neuromuscular theory, muscles are not active as prime movers of the vocal folds; rather, they tune the vocal folds by adjusting their length, tension, and mass, thus regulating the glottic resistance. The myoelastic theory continues to undergo refinement, particularly in relation to the role of the varying mass of the vocal cords during phonation (Titze, 1980).

Modulation of vocal pitch (fundamental frequency), vocal register, and intensity is a complex process requiring coordination of all intrinsic and extrinsic laryngeal muscles. Hirano (1987) studied control of vocal register (falsetto, modal, and vocal fry), regulation of fundamental frequency, and vocal intensity using EMG in singers and nonsingers. The vocalis muscle and lateral cricoarytenoid muscle are active predominately in the heavier registers (modal and fry). Register shift is accomplished predominately by change in vocalis muscle activity and to some degree lateral cricoarytenoid and interarytenoid muscle contraction. Shifts from light (falsetto) to heavy (modal) registers is associated with an increase in vocalis activity, whereas changes in the opposite direction (heavy to light) are associated with decreased vocalis activity. Cricothyroid muscle activity, although present, does not have a

predictable pattern of activation during change in vocal register.

Muscle activity associated with modulation of fundamental frequency within a given register is more predictable. For example, within the modal register, changes in the balance between vocalis and cricothyroid muscles account for shift between chest voice, mid voice, and head voice. Increased cricothyroid activity relative to vocalis activity occurs as the fundamental frequency is increased in the transition to head voice. In falsetto, cricothyroid activity is increased while vocalis activity is nearly absent (Hirano, 1987).

Increases in vocal intensity are associated with greatest change in vocalis muscle activity, independent of fundamental frequency. The vocalis muscle opposes the cricothyroid muscle and functions to loosen and thicken the vocal fold mucosa. These changes are also associated with increased glottal resistance, an important factor in increasing vocal intensity. Lateral cricoarytenoid and interarytenoid muscle activity levels, to a lesser degree, parallel vocalis activity, whereas cricothyroid activity is inversely related to change in vocal intensity. Since elevated glottic pressure and increased glottal resistance result in an increase in fundamental frequency, a decrease in cricothyroid muscle activity is probably a response to regulate the fundamental frequency (Hirano, 1987).

### **Effort closure**

Closure of the glottis is important to increase intrathoracic and intraabdominal pressure (for example, when lifting weights or coughing or during defecation or micturition). Because the laryngeal vestibule closes during a straining effort, laryngoscopy has provided limited information. Consequently, much of our understanding of this event has come from tomographic, laminographic, or electromyographic studies (Adrian et al, 1953, 1954; Faaborg-Andersen, 1957; Hollien and Curtis, 1960). These studies have shown that both the vocal and vestibular folds are approximated during effort closure and that the laryngeal ventricle is collapsed. Since patients with recurrent laryngeal palsy are able to achieve substantial closure of the airway during coughing (Adrian et al, 1954), other mechanisms must also participate during coughing. Fink (1956, 1975) has proposed that there is a mechanical coupling mechanism that implicates the preepiglottic tissues and assists in closure when the thyroid cartilage is elevated during coughing.

### **Closure during swallowing**

Closure of the larynx during swallowing appears to represent the maximum effort of any of the closure mechanisms: approximation of vocal folds, vestibular folds, and aryepiglottic folds and retroversion of the epiglottis. Movement of the epiglottis is the more significant added feature when compared with effort closure. Movement of the epiglottis is also the more controversial. Many mechanisms have been proposed to explain the flap-valve motion of the epiglottis. The most popular is that the aryepiglottic muscle draws it down. Fink and Demarest (1978) have proposed an interesting geometric argument suggesting that the downward movement of the epiglottis is in response to mechanical elevation of the thyroid and lateral forces on the base of the cartilage by the preepiglottic tissues.

## Motor and Sensory Innervation

Since the muscles of the larynx are derived from branchial arch mesoderm, the motor fibers begin in the medulla. Previous studies in rats (Hinrichsen and Ryan, 1981), rabbits (Davis and Nail, 1984), cats (Yoshida et al, 1982), and monkeys (Yoshida et al, 1987) using horseradish peroxidase retrograde labeling have localized the somata of motoneurons innervating laryngeal muscles to the ipsilateral nucleus ambiguus (NA), retrofacial nucleus, and the dorsal motor nucleus of cranial nerve X. The recurrent laryngeal nerve axons arise from motoneuron cell bodies in the NA. The NA maintains a narrow position in the brain stem at the level of the upper medulla and lower pons and lies adjacent to the ventral respiratory group motoneurons in the lateral tegmental region in the brain stem. The ventral respiratory group contains motoneurons controlling the contraction of the diaphragm and other inspiratory and expiratory musculature and appears to provide respiratory input to the laryngeal motoneurons (Ellenberger and Feldman, 1990; Ellenberger et al, 1990). Although slight variation occurs between different species, the cell bodies of motoneurons innervating the cricothyroid muscle in monkeys are found in the more rostral half of the NA dorsomedially, as well as in the adjacent retrofacial nucleus. The cells bodies of the motoneurons innervating the posterior cricoarytenoid (PCA), thyroarytenoid (TA), lateral cricoarytenoid (LCA), and interarytenoid (IA) muscles are seen in the caudal half of the NA. The cell bodies of the PCA neurons are localized medially, the TA group laterally, and the LCA and IA sandwiched in between. Little or no regional overlap of motoneuron pools is seen, although double-labeled cells innervating two synergistic muscles (the TA and the LCA) have been identified (Flint et al, 1991; Hisa and Sato, 1987).

Axonal processes from the NA contribute to both the vagus nerve and the cranial portion of the eleventh cranial nerve (CN XI). Fibers from CN XI, however, join the vagus nerve shortly after they emerge from the jugular foramen. In essence, all of the innervation of the larynx is carried by the vagus nerve inferior to the level of the jugular foramen. As the vagus nerve travels down the neck in the carotid sheath, two laryngeal branches are given off: the superior and the recurrent laryngeal nerves. Both of these branches contain motor and sensory fibers for the larynx. Motor fibers in the superior laryngeal nerve continue into the external laryngeal nerve but are not carried by the superior laryngeal nerve, since it contains only sensory fibers. The external laryngeal nerve is distributed to the cricothyroid muscle, as well as to the inferior constrictor muscle of the pharynx. All of the intrinsic muscles of the larynx are supplied by the recurrent laryngeal nerve, which enters the larynx at the cricoid cartilage between the muscle fibers of the cricopharyngeus muscle and the esophagus (see Figs. 94-8 and 94-9). All the muscles are innervated unilaterally from their respective vagus, with the exception of the interarytenoid muscle, which receives innervation from both vagi. Only that muscle of the larynx has been noted to have bilateral innervation.

Innervation of the laryngeal mucosa is carried by both the internal and the recurrent laryngeal nerves. Sensory fibers from the laryngeal mucosa at the level of the false vocal cord and the piriform sinus return via the internal laryngeal branch of the superior laryngeal nerve (see Figs. 94-8 and 94-9). These sensory axons ascend in the vagus nerve to the inferior ganglion of the vagus nerve. The cell bodies are located in the rostral half of the nodose ganglion (Yoshida et al, 1989). From the ganglion the central processes of these neurons ascend superiorly in the vagus nerve, entering the medulla, where they synapse in the ipsilateral nucleus dorsomedialis, nucleus solitarius, and nucleus ambiguus (Goding et al,

1987; Kalia and Mesulam, 1980). Similarly, sensory fibers from the inferior half of the larynx (mucosa of the true vocal fold, subglottic mucosa, and adjacent esophageal mucosa) are carried via the recurrent laryngeal nerve, ascending in the vagus nerve to the inferior ganglion of the vagus nerve. The cell bodies of these neurons are also located in the inferior ganglion of the vagus nerve and project to the nucleus solitarius and nucleus ambiguus.

Local anesthesia of the supraventricular portion of the larynx can be accomplished by making use of one's knowledge of the anatomy of the internal laryngeal nerve. In the region of the piriform sinus, only a thin veil of mucosa covers the terminals of the internal laryngeal nerve. A cocaine pledget placed by direct laryngoscopy into the piriform recess bilaterally generally provides adequate topical anesthesia. Alternatively, the mucosa of the piriform sinus may be anesthetized by a cutaneous approach after a needle has been inserted through the thyrohyoid membrane and the submucosal space of the sinus infiltrated with an appropriate anesthetic drug.

### **Autonomic Innervation**

The larynx receives autonomic innervation - adrenergic and cholinergic - from the superior cervical ganglia and the vagus nerve, respectively. The neurons and fibers of the autonomic nervous system are neuropeptide-containing structures. Two neuropeptides associated with specific autonomic function, vasoactive intestinal peptide (VIP) and neuropeptide Y (NPY), have been identified within laryngeal nerve fibers (Basterra et al, 1989). Substance P, a neurotransmitter found in both sensory and autonomic nerve fibers, has also been found in intraepithelial nerve corpuscles, fibers within submucosal glands, and fibers adjacent to laryngeal arterioles within the canine larynx (Shin et al, 1987).

VIP has strong vasodilatory activity, relaxes smooth muscle fibers, and regulates exocrine gland secretion. Within the larynx, VIP is observed within parasympathetic (cholinergic) neurons that innervate arteries and minor salivary glands in the submucosal space of the vocal fold (Basterra et al, 1989).

NPY is found within sympathetic (noradrenergic) neurons and has dose-dependent constrictor activity on arteries and arterioles. NPY is closely associated with laryngeal arteries and, to a lesser extent, glandular acini. The primary role of both VIP and NPY is to regulate vessel caliber and glandular secretion, thus affecting change in vocal fold mass and vibratory characteristics. Presumably this would explain the emotional or stress-related changes in vocal quality (Basterra et al, 1989).

### **Blood Supply**

A bilevel blood supply exists for the larynx: the superior and inferior laryngeal arteries (see Fig. 94-9). The superior laryngeal artery is a branch of the superior thyroid artery, derived from the external carotid artery. The superior thyroid artery is, in fact, the first anterior branch of the external carotid, although on occasion it may arise as a branch of the common carotid artery. It is important that one recognize this variation when ligating the external carotid artery for chronic epistaxis, since the common carotid may be mistaken for the external carotid and be inadvertently ligated. As the superior thyroid artery descends the carotid triangle, the superior laryngeal artery crosses transversely and pierces the thyrohyoid

membrane where it supplies the laryngeal mucosa. Distribution of the vessel includes the piriform sinus and the medial surface of the quadrangular membrane as inferiorly as the false vocal fold. The inferior laryngeal artery is similarly derived from the inferior thyroid artery, which originates from the thyrocervical trunk of the subclavian vein. The inferior thyroid artery enters the larynx, along with the recurrent laryngeal nerve, at the junction of the cricopharyngeus and esophageal muscle fibers. It supplies the muscles attaching to the arytenoid cartilages, as well as the laryngeal mucosa adjacent to the false vocal fold and laryngeal ventricle. The branches of the inferior laryngeal artery also anastomose with those of the superior laryngeal artery.

### **Venous Drainage**

The venous drainage of the larynx follows the same pattern as the arterial supply. A superior laryngeal vein parallels the course of the superior laryngeal artery and eventually empties into the internal jugular vein. The inferior laryngeal vein is a tributary of the thyrocervical trunk of the subclavian vein.

### **Lymphatic Drainage**

The lymphatic drainage of the larynx parallels its dual blood supply. Lymphatic flow from the level of the false cords follows the superior laryngeal vessels superiorly to the level of the carotid sheath. Here, the afferent lymphatic vessels join the jugular chain of lymph nodes and vessels that ultimately form the jugular lymph trunk. The jugular lymph trunk on the right side enters the venous system at the jugulosubclavian vein on the right side or at the thoracic duct on the left side. Lymphatic afferents from the superior half of the larynx therefore usually send lymph to the juguloomohyoid nodes, which are located on the jugular vein and carotid sheath, at the point where the larynx is crossed by the omohyoid muscle. In contrast, lymphatics following the inferior laryngeal vessels may have connections with the pretracheal nodes before entering the deep cervical nodes of the jugular chain near the subclavian vein. These lymphatics then proceed to enter the jugular lymph trunks and the venous system. For this reason, subglottic masses have a more direct lymphatic route to the venous system than does lymph flowing from a mass in the supraventricular region of the larynx.